

Mini-Forum Research Report

Symptomatic Treatment of Memory Decline in Alzheimer's Disease by Deep Brain Stimulation: A Feasibility Study

Denys Fontaine^{a,b,*}, Audrey Deudon^c, Jean Jacques Lemaire^{b,d}, Micheline Razzouk^e, Philippe Viau^c, Jacques Darcourt^e and Philippe Robert^{c,f}

^a*Service de Neurochirurgie, CHU de Nice, Nice, France*

^b*IGCN-EA 7282 (Image-Guided Clinical Neuroscience and Connectomics), UMR 6284 ISIT, Uda, Clermont-Ferrand, France*

^c*Centre Mémoire de Ressources et de Recherche, CHU de Nice, Nice, France*

^d*Service de Neurochirurgie, CHU de Clermont-Ferrand, Clermont-Ferrand, France*

^e*Service de Médecine Nucléaire, CHU de Nice, Nice, France*

^f*EA CoBTek, University of Nice Sophia Antipolis, France*

Accepted 27 September 2012

Abstract. Recent studies have suggested that memory circuits can be modulated by deep brain stimulation (DBS). This propriety might be used to slow down cognitive decline in patients suffering from Alzheimer's disease (AD). We conducted a prospective study to evaluate the feasibility and safety of DBS in AD patients with mild cognitive decline. Inclusion criteria were: patients (<70 years old) with AD diagnosed for less than 2 years, predominant impairment of episodic memory, and Mini-Mental Status Exam (MMSE) score between 20 and 24. The fornix was stimulated bilaterally by electrodes implanted stereotactically in the hypothalamus. Clinical, biological, neuropsychological, and imaging evaluations were conducted 3 months before surgery and 3, 6, and 12 months thereafter. During the one year-period of inclusion, 110 patients with recently diagnosed AD and predominant impairment of episodic memory were screened. Only 9 patients (8.2%) fulfilled all the inclusion criteria. Finally, just one patient accepted to be operated (acceptance rate 11.1%) and completed the study. No complications occurred and the stimulation was perfectly tolerated. After one year of stimulation, the memory scores (MMSE, ADAS-Cog, Free and Cued Selective Reminding Test) were stabilized compared to baseline, and mesial temporal lobes metabolism increased. This pilot study provides new data about the safety of fornix DBS in the hypothalamus. However, it suggests that only a small proportion of AD patients might be interested in this approach and that the acceptance of DBS by AD patients was low, raising questions about the relevance of this approach to meet the expectations of these patients.

Keywords: Alzheimer's disease, deep brain stimulation, dementia, fornix, hypothalamus

INTRODUCTION

In France, a third Alzheimer Plan was launched in 2008 (French National Plan for "Alzheimer and

Related Disorders" 2008–2012) [1] strengthening research on Alzheimer's disease (AD) and related disorders, promoting earlier diagnosis, and improving both patient management and support for carers. As such, the plan encourages clinical centers belonging to the nationwide network of 27 "memory resource and research centers" (CMRRs: *Centres mémoire de ressources et de recherche*) to submit projects focusing

*Correspondence to: Docteur Denys Fontaine, Service de Neurochirurgie, Hôpital Pasteur, 30 avenue de la voie romaine, 06000 Nice, France. Tel: +33 492038528; Fax: +33 492038450; E-mail: fontaine.d@chu-nice.fr.

on innovative therapeutic work. AD is a slow progressive disorder, with insidious onset and progressive impairment of episodic memory leading to global cognitive decline including aphasia, apraxia, and agnosia [2, 3]. No current therapies prevent or cure AD [4]. Pathological processes lead to progressive disruption of neural network activity with a predilection for neuronal circuits dedicated to memory [2, 3].

In 2007, an international work group (IWG) led by Bruno Dubois [5] offered a redefinition of AD as a dual clinico-biological syndrome that can be recognized *in vivo*, prior to the onset of dementia, on the basis of i) a specific core clinical phenotype comprised of an amnesic syndrome of the hippocampal type and ii) supportive evidence from biomarkers reflecting the presence of Alzheimer-type pathology. Within the lexicon of the criteria [6], the label of AD is now restricted to the clinical disorder that starts with the onset of the first specific clinical symptoms of the disease, and encompasses both the prodementia and dementia phases. Thus, AD refers to the whole spectrum of the clinical phase of the disease and is not restricted to the dementia syndrome. The diagnosis is now established *in vivo* and relies on a dual clinico-biological entity that requires the evidence of both specific memory changes and *in vivo* markers of AD pathology that can include: cerebrospinal fluid (CSF) amyloid- β , total tau, and phospho-tau; retention of specific positron emission tomography (PET) amyloid tracers; medial temporal lobe atrophy on magnetic resonance imaging (MRI); and/or temporal/parietal hypometabolism on fluorodeoxyglucose PET. The clinical phenotype can be typical or atypical. Additionally, two different stages might still be meaningful: a prodromal and a dementia phase. Recently the National Institute on Aging and Alzheimer's Association (NIA/AA) convened work groups that proposed alternative diagnostic formulations for diagnoses of preclinical AD, mild cognitive impairment (MCI) due to AD, and AD dementia [7–9]. NIA/AA criteria utilize "MCI" to describe this state of cognitive compromise that does not meet criteria for dementia. The clinical criteria for MCI are the same as those previously published [10]. MCI is an etiologically and prognostically nonspecific syndrome with some patients returning to normal, some progressing to AD, some progressing to non-AD dementias, and some remaining with MCI for long periods of time [7, 8]. The NIA/AA criteria have several strengths. They can be used when no biomarkers are available by applying conventional clinical criteria for MCI. They also have a wider scope than the IWG/Dubois criteria and allow for biomarker-based

diagnosis of non-AD-related MCI and dementia syndromes.

Very preliminary results showed that memory circuits could be modulated using deep brain stimulation (DBS) electrodes in human subjects without memory impairment [11, 12]. Animal studies and electrophysiological and metabolic data have suggested several mechanisms of action: resetting of hippocampal theta phase, increase of hippocampal neurogenesis, enhanced long term potentiation, and diffuse reactivation of hypoactive neo-cortical associative regions belonging to the brain default network [12–20].

This data suggested that DBS could be used as a symptomatic treatment of memory impairment in patients with AD. In a recent phase study, chronic DBS of the fornix led to the stabilization or slowing down of the memory decline in a few patients with mild AD, one year after surgery [16]. However, more data is mandatory to assess the short- and long-term efficacy, the tolerance, and the relevance of this approach in patients suffering from AD. Considering the invasiveness of DBS, we conducted a prospective study to assess the feasibility and tolerance of peri-fornical DBS in a population of mild AD patients.

METHODS

Patients

We conducted a prospective pilot study whose primary objective was to evaluate the feasibility and safety of DBS of the fornix in the hypothalamus in mild AD patients with mild cognitive decline. This study has been granted by the French National AD Plan and approved by the local ethical committee (Comité de Protection des Personnes Sud Méditerranée 2).

Patients were screened at the Nice Memory Resource and Research Centre (CMRR). Patients had to be under 65 years of age (then extended to 70 by an amendment of the protocol after 6 months of inclusion). They were also required to meet AD DSM IV criteria [21], for less than 2 years, with predominant impairment of episodic memory evaluated by the Free and Cued Selective Reminding Test (FCSRT) [22] and Mini Mental State Exam (MMSE) [23] score between 20 and 24. All these tests were done in everyday clinical practice in the center. The following procedure was applied with all regular patients coming to consultation at the CMRR: When a patient satisfied the inclusion criteria, the clinician discussed with her/him (in the presence of the caregiver) his/her interest to be included in a clinical trial using DBS. During this

discussion, the clinicians (PR, AD) described state-of-the-art treatments of AD as well as the potential interest of DBS.

If the patient and caregiver were interested, a second consultation was proposed with the neurosurgeon in charge of the study (DF). During this discussion, the DBS technique was described in details. Only after these steps were performed, we proposed to the patient and caregiver to sign the informed consent.

Patients were not included in the cases of associated DSM IV axis I pathology, contra-indication to MRI or surgery, or abnormality on the preoperative MRI. *In vivo* markers of AD pathology (MRI and/or CSF and or PET) were also proposed to the patients.

Clinical assessment

The primary endpoint was the feasibility, defined as the proportion of patients able to undergo the whole study protocol (meaning the screening, information, surgery, chronic stimulation, and evaluation processes) without serious adverse event. The efficacy of fornix DBS was evaluated by several cognitive scales including the MMSE [23], the FCSRT, the Alzheimer's Disease Assessment Scale, Cognitive Subscale (ADAS-Cog) [24], the Wechsler Adult Intelligence Scale abbreviated version [25], Trail Making Test (TMT) A and B [26], and the Rey figure [27], at 3 months and one week before surgery, and 3, 6, and 12 months thereafter. Global improvement has been evaluated by the Clinical Global Impression of Change [28] of the patient and activities of daily living (ADL) [28]. Anxiety and mood were assessed respectively by the Hamilton Anxiety Rating and Montgomery-Asberg depression scales [29, 30]. As the stimulation was delivered within the hypothalamus, the safety was assessed by systematic clinical examination, including supine and standing blood pressure, heart rate, weight, body temperature, and by recording of any change in thirst, appetite, libido, sleep-walking cycle and behavior. Electrolyte balance and hormonal functions (thyroid hormones, TSH, ACTH, cortisol, SDHEA, insulin, prolactin, testosterone, estradiol, LH, FSH, GH, IGF-1) were assessed at each evaluation. Cerebral metabolism was evaluated after 6 and 12 months of chronic stimulation compared to baseline, by 18 fluoro desoxy-glucose (18FDG) positron emission tomography. These studies were performed (at baseline, 6 and 12 months after surgery), 200 MBq of 18FDG were injected and then the images were acquired 30 min post-injection on a TEP-CT camera (Discovery ST, GE) using 3D acquisition mode. 18FDG TEP images

were analyzed using the Scenium[®] software (Siemens Medical Solutions, USA). This software allows co-registration of the individual 3D brain PET studies to a normal data base and provides an automatic template of regions of interest. Individual SUV values of each anatomical region of interest (ROI) are compared to the normal data base values and expressed as number of standard deviations from the mean normal values.

Surgery and stimulation

A Fischer ZD stereotactic frame was applied to the patient's head under local anesthesia the morning of the procedure. Stereotactic T2-weighted and 3D T1-weighted MRI of the brain were obtained and merged after co-registration. The target was chosen 2 mm anterior and parallel to the vertical portion of the fornix within the hypothalamus, as previously described [16]. Electrodes (model 3387; Medtronic, Minneapolis, USA) were implanted bilaterally under local anesthesia. Intraoperative stimulation (up to 4 V) was applied to check the absence of side effects. The electrodes were then connected to a subcutaneous pectoral generator (model Kinetra, Medtronic) under general anesthesia. Permanent stimulation (bipolar between contacts 0 and 1, frequency 130 Hz, pulse width 210 ms, voltage 2.5 V) was delivered from the first postoperative week to the end of the study. The coordinates of the electrodes stimulating contacts, relative to the bi-commissural line and plans, were calculated on postoperative MRI (3D T1 weighted sequence, slice thickness 1.2 mm). The intra hypothalamic location of the stimulating contacts was studied using a 3D MRI-based 4.7-Tesla atlas, after projection of the contacts using the same anatomic landmarks, i.e., bi-commissural line and related plans, according to a method already described [31].

RESULTS

During the one year-period of inclusion, 110 patients with recently diagnosed AD and predominant impairment of episodic memory were screened by the principal investigator (PR) in a consultation dedicated to memory disturbances. Only 9 out of 110 patients fulfilled all the inclusion criteria. Other patients were not included due to being too old (57 cases), MMSE being too low (12 cases), having dementia of mixed (vascular) origin (16 cases), or other miscellaneous reasons (16 cases). Four out of 9 patients accepted the idea to be included in the study but only two of them finally

Table 1
Cognitive and behavioral assessment of Mrs PC across the study, 3 months (M-3) and one week (D-7) before surgery and after 3 (M3), 6 (M6) and 12 (M12) months of continuous stimulation

		M-3	D-7	M3	M6	M12
MMSE (centile 5 = 22)		23	29	25	26	24
ADAS-Cog		12.25	9	9.41	10	9.91
Digit span	Normal order (m = 5 ± 1.22)	4	4		4	4
	Reverse order (m = 3.51 ± 0.96)	3	3		3	2
FCSRT	Total immediate recall (/48)	27	39		17	32
	Total differed recall (/16) (m = 15.2 ± 1.4)	6	13		6	9
Rey figure (Copy) (m = 32)		30	28		26	27
DO 80 (cut off = 69)		79	79		80	78
Stroop test	Color (s) (cut off = 110)	80	84		76	85
	Word (s) (cut off = 67)	58	55		55	55
	Interference (s) (cut off = 347)	170	135		141	142
Trail Making Test (TMT)	TMT-A (s) (cut off = 134)	43	31	38	51	34
	TMT-B (s) (cut off = 284)	109	132	150	232	150
Verbal fluency	Phonemic (m = 14.71 ± 7.56)	14	10	15	14	13
	Semantic (m = 25.78 ± 5.32)	17	19	20	22	26
Six elements (rank) (cut off = 2)		4 or 5	4 or 5		2 or 3	2 or 3
Brixton test (errors) (cut off = 34)		19	35		18	17
Double task of Baddeley (mu)		84.52	68.64		95.12	90.47
WCST (/20) (cut off = 2)		3	ND		6	15
WAIS-R Short version (QI)		87			87	87
Clinical Global Impression of Change (CGI-I)		NA	NA	No change	Slightly improved	No change
ADL Lawton (/8; 8 = autonomy)		8	8	8	8	8
Katz's scale (/6; 0 = autonomy)		0	0	0	1	1
Apathy inventory (caregiver)	Emotional blunting	0	0		0	0
	Lack of interest	2	0		0	0
Apathy inventory (patient)	Emotional blunting	0	0		2.5	0
	Lack of initiative	6	6		2.3	0
	Lack of interest	4	4		3.2	4
MADRS (cut off = 15)		15	17	8	8	10
HARS (cut off = 30)		10	12	10	14	10
Neuropsychiatric inventory	Delusions	0	0	0	6	0
	Hallucinations	0	0	0	0	0
	Agitation/aggression	2	0	0	0	4
	Depression/dysphoria	0	0	0	0	0
	Anxiety	0	0	0	0	0
	Elation/euphoria	0	0	0	0	0
	Apathy/indifference	2	0	0	0	0
	Disinhibition	0	0	0	0	0
	Irritability/lability	2	2	0	4	4
	Aberrant motor behavior	0	0	0	0	0
	Sleep and nighttime behavior disorders	6	0	0	0	0

MMSE, Mini Mental Status Exam; ADAS-Cog, Alzheimer's Disease Assessment Scale, Cognitive Subscale; FCSRT, Free and Cued Selective Reminding Test; WCST, Wisconsin Card Sorting Test; WAIS, Wechsler Adult Intelligence Scale; CGI-I, Clinical Global Impression of Change; ADL, activities of daily living; MADRS, Montgomery-Asberg depression; HARS, Hamilton Anxiety Rating Scale.

signed the informed consent. One patient withdrew her consent after signature. Finally, only one patient (Mrs. PC) was operated upon and completed the study.

Mrs. PC was a right-handed female, aged 71. Before participating in the study, Mrs. PC was referred by her general practitioner to the Gerontology unit of the University hospital of Nice, for memory complaints. Since the first consultation in March 2008, Mrs. PC underwent clinical examination as well as global cognitive

assessment. MMSE scores were 28 (March 2008), 24 (March 2009), and 28 (April 2010). In March 2009, Mrs. PC underwent her first FCSRT whose results indicated impairment of episodic memory. After information about the DBS study was published in the local newspaper, Mrs. PC went to the memory consultation spontaneously. She immediately indicated that she was willing to participate in the study. The first interview with the patient indicated that Mrs. PC presented

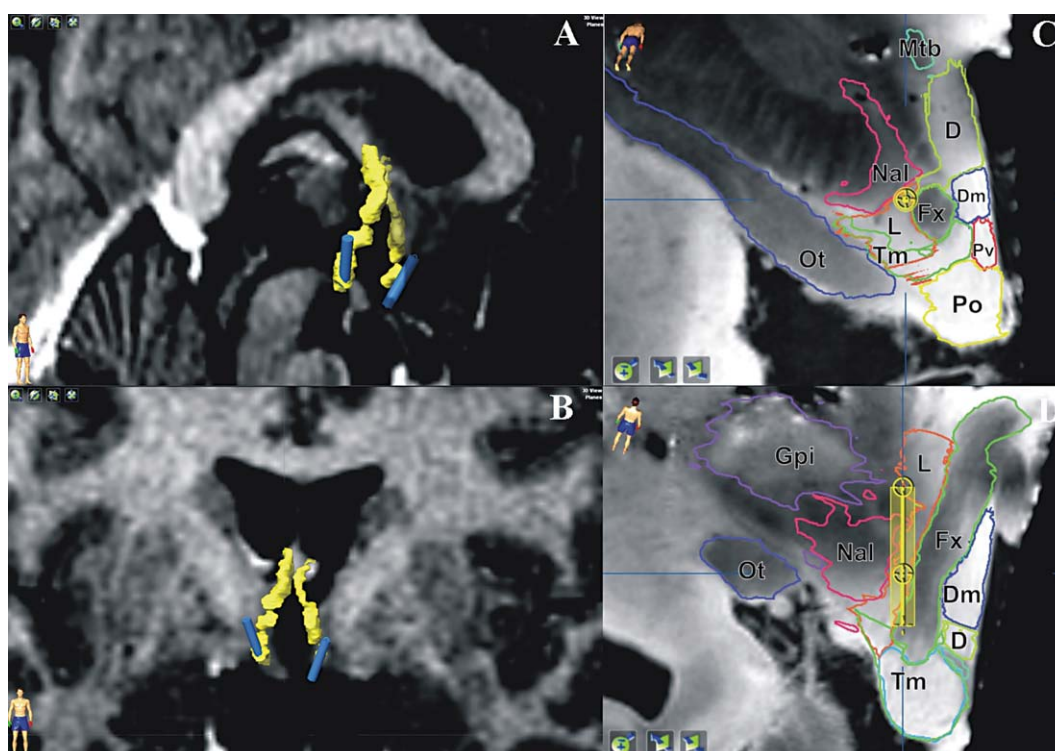


Fig. 1. Location of the electrodes within the hypothalamus. A, B) Antero-lateral (A) and frontal (B) 3D views showing the location of the four-contact electrodes (blue cylinders) close to the fornices (yellow; manual segmentation); sagittal (A) and coronal (B) MRI slices going through the hypothalamus are displayed. C, D) Co-registration of the right electrode (according to stereotactic coordinates relative to the midpoint along the commissural plane) with the stereotactic 3D 4.7-T MRI atlas; perpendicular (C) and parallel (D) reconstructed slices along the electrode axis are displayed. All the contacts were located near the fornix within the hypothalamus [41]: fornix (Fx); mamillary body within the tuberomammillary nucleus (Tm); mamillo-thalamic bundle (Mtb); optic tract (Ot); globus pallidum internus (Gpi); nucleus of the ansa lenticularis (Nal); lateral (L), dorsal (D), dorso-medial (Dm), paraventricular (Pv) and pre-optic (Po) hypothalamic nuclei.

an excessive emotionality and anxiety about everyday things and health problem. However, she did not meet the DSM IV criteria for personality disorders or anxiety or depression.

Table 1 shows the results of the full neuropsychological and behavioral examination performance done after the inclusion, 3 months before the surgery (M-3). FCSRT scores confirmed episodic memory impairment. Considering both free and cued recalls, there was an encoding, retrieval, and storage deficit, but it seemed that Mrs. PC was still capable of learning, considering the performance rising through the three successive trials. TMT scores indicated a low cognitive speed processing and an executive functioning impairment (mental flexibility and switching capacity) (TMT A $p=30$; TMT B $p=75$). Structural MRI showed mild hippocampal bilateral atrophy. The CSF examination indicated presence of amyloidopathy compatible with the diagnosis of AD ($A\beta_{42}=345$ ng/ml, total tau = 345 ng/ml, p-tau 181 = 78 ng/ml, index $A\beta_{42}/$

p-tau 181 = 7.49). FDG PET scan showed a discrete hypometabolism on medial temporal regions.

Surgery was well tolerated. No peri-operative complication occurred. One year after surgery, no change in behavior and no clinical or biological adverse events were reported except a discrete increase of irritability. Postoperative imaging confirmed that the electrodes were implanted within the hypothalamus, close to the fornix (Fig. 1).

After surgery, behavioral and cognitive evaluations remained globally below the normative data for her age and socio-cultural level, especially for memory and executive functioning tests, despite fluctuations (Table 1). Anxiety and mood were slightly improved but remained dependent on the environment. Her subjective feeling was improved by the surgery. Mrs. PC's husband also reported, after an improvement at month 6, a stabilization of her mood, behavior, and daily functioning. Changes visually observed on FDG PET imaging, in particular in the temporal regions,

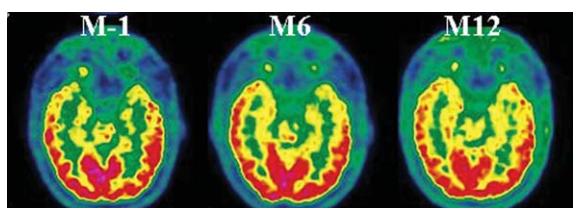


Fig. 2. PET scans in one AD patient before and after 6 and 12 months of continuous bilateral electrical stimulation of the fornix/hypothalamus. Representative axial sections suggest a slight but not significant increase in brain metabolism at 12 months, particularly in both medial temporal lobes.

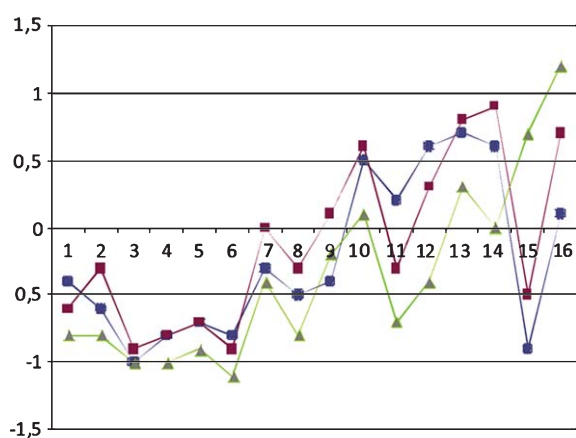


Fig. 3. ^{18}F FDG uptake values expressed as number of standard deviations from the mean values of the Scenium[®] normal data base. Values are presented as blue dots at baseline; red squares at 6 months and green triangles at 12 months. Anatomical ROIs are presented on the x axis: 1 left frontal lobe, 2 right frontal lobe, 3 left temporal lobe, 4 right temporal lobe, 5 left parietal lobe, 6 right parietal lobe, 7 left cingulate and paracingulate gyri, 8 right cingulate and paracingulate gyri, 9 left occipital lobe, 10 right occipital lobe, 11 left calcarine fissure and surrounding cortex, 12 right calcarine fissure and surrounding cortex, 13 left basal ganglia, 14 right basal ganglia, 15 left mesial temporal lobe, 16 right mesial temporal. These data show that ^{18}F FDG uptake increased with time in the mesial temporal lobes, especially on the left side.

were considered as non-significant (Fig. 2). However, on quantitative analysis, mesial temporal FDG uptake, expressed in standard deviations from the normal data base mean values, increased from baseline at 6 and 12 months (Fig. 3). On the left side, mesial temporal ^{18}F FDG uptake value was equal to -0.9 SD from the normal data base value at baseline and improved after 6 months (-0.5 SD) and after 12 months ($+0.7$ SD). On the right side, the mesial temporal ^{18}F FDG uptake value was equal to $+0.1$ SD from the normal data base mean value at baseline and improved after 6 months ($+0.7$ SD) and after 12 months ($+1.2$ SD).

DISCUSSION

Our study added data concerning the feasibility and tolerance of fornix DBS in patients suffering from mild AD. However, in the light of our data, our current inclusion criteria appear too restrictive and might limit this symptomatic treatment to a small proportion of AD patients.

Feasibility and safety

Our data has shown that, although most of the screened patients were able to undergo the process of selection and information about the technique, only one (0.9%) was finally operated upon. In this patient, the surgery, the chronic stimulation, and the evaluation process were feasible and well tolerated. The anatomical study of the electrodes location confirmed their implantation within the hypothalamus (Fig. 3). No adverse event due to fornix chronic DBS has been reported so far in the literature, but only 8 patients have been operated upon [11, 16], including our case. Although DBS of the posterior, ventro-medial, and ventro-lateral hypothalamus can induce autonomic, oculomotor, behavioral, or emotional responses in humans [32–37], DBS of the fornix within the hypothalamus appears to be safe when using stimulation amplitudes inferior to 5 V [11, 16], even in old patients suffering from AD.

Clinical effect

Our study was not designed to assess the efficacy of DBS in AD, especially in controlled conditions. However, cognitive scores of our patient were stabilized after one year of chronic stimulation compared to baseline, although these scores were declining before surgery. Mrs. PC's clinical characteristics were compatible with a diagnosis of AD at the pre-dementia phase. Results of the FCSRT demonstrated a specific amnesic syndrome, and there was also supportive evidence from biomarkers reflecting the presence of Alzheimer-type pathology. However, there was no major activity of daily living impairment. In addition, the pre-inclusion follow-up showed cognitive fluctuations but not a major and rapid decline. This is also consistent with the diagnosis of MCI according to the NIA/AA criteria [7]. After a global improvement one week before the surgery, the patient's cognitive performances worsened 6 months after surgery and returned to their initial level 12 months after surgery. In parallel, there was no major change in behavior

and mood. The personality characteristics of Mrs. PC certainly played a role to facilitate her involvement in the study and might only partially explain the transient improvement observed one week before the intervention. However, they cannot explain the overall cognitive performances during the postoperative follow-up. We cannot exclude that the stabilization of cognitive decline was due to spontaneous evolution of the disease. However, PET imaging was in favor of an improvement of mesial temporal metabolism due to DBS. Although this improvement was slight, it appears reliable due to its consistent evolution during time; whereas in other ROIs such as temporal and parietal lobes, the uptake values remained stable around 1 SD below the normal values. Such an improvement is not common in spontaneous AD evolution. Taken together, these results and the good tolerance of DBS in AD patients were encouraging.

Patient selection and acceptance of DBS approach

Our study showed that only 8.2% of the ongoing AD patients might be eligible for DBS, considering our inclusion criteria. Because the concept of DBS of the fornix (part of the Papez' circuit) is to modulate neural circuits involved in memory, we restricted this approach to AD patients with predominant impairment of episodic memory. In pioneer studies, fornix DBS predominantly improved verbal recollection [11] and the recall and recognition components of the ADAS-cog [16]. Other cognitive dimensions, including apraxia and alertness, might be modulated by DBS targeting the nucleus basalis of Meynert (NBM) [38, 39]. Inclusion in our study was restricted to patients with mild ($MMSE \geq 20$) and recently diagnosed AD. This was decided following the results of Laxton et al. who reported that the less severely affected patients were the less likely to decline after DBS [16]. This was consistent with the notions that better-preserved circuit integrity, as may be expected in milder patients, may be a predictor of response to DBS. For the same reason, patients over 65 years old were initially not included, but we observed that this was the main limiting factor for recruitment, excluding an excessive number of otherwise eligible patients. Our memory center is located in a geriatric department and this may explain that patients coming in consultation were often older than 65. Actually, it was only after authorization of the amendment to include patients between 65 and 70 years old by the ethical committee that we selected the patients fulfilling all the inclusion criteria.

Public information concerning the study was twice advertised in local newspapers. Following these advertisements, a non-negligible number of patients came to the consultation specifically to be included in the study. However it was not possible to include them, due to age and severity of dementia criteria. In addition, the complete description of the study procedure also reduced the number of patient willing to participate. Only 5 out of the 9 eligible patients accepted to meet the neurosurgeon for the second consultation. Finally only one patient was operated upon and completed the study, which accounted for 0.9% and 11.1% of the screened and eligible patients respectively.

The acceptance rate of this approach by mild AD patients was consequently 11.1%, which was low considering the lack of alternative efficient treatment. This result contrasted with the relatively good acceptance of the surgical approach by the families and caregivers. In our opinion, this low acceptance rate might be explain by the invasiveness of the technique on one hand, and the patients' anosognosia and denial concerning the ineluctable cognitive decline on the other hand, which resulted in an underestimation of the benefit/risk ratio. Moreover DBS was presented as a symptomatic treatment whose aim was to transiently stabilize the memory decline, but not to improve memory or to cure the disease. Finally, the lack of data from large studies and the random efficacy in the pilot study probably decreased the patients' acceptance for the surgery.

Perspectives

Despite the simplified implantation technique, the good tolerance of surgery and chronic fornix DBS, this approach did not seem to reach the expectations of mild AD patients. This issue might be similar with other DBS targets, but might be tempered if other cognitive aspects could be also improved, as it has been suggested for NBM-DBS. However, neuronal degeneration of the NBM occurs early in the course of the disease, making dubious the long-term interest of NBM-DBS. Stimulation of other targets belonging to the memory circuits, such as the anterior nucleus of the thalamus [40] and the entorhinal cortex [17], enhanced memory performances in rodents, but have not been used in patients with dementia. Our PET study showed an increased metabolism in the mesial temporal lobes following DBS of the fornix, concordant with previous data [11, 16]. These findings suggest that DBS could act through antidromic stimulation of the hippocampus, which could lead to the facilitation of processes driving memory encoding and/or to the increase of

hippocampal neurogenesis, similar to DBS of other targets belonging to the Papez' circuit [17, 18, 40].

The benefit/risk ratio of DBS might be more favorable in early stages of AD or in patients suffering from MCI because the memory circuits integrity may be preserved for a long time and, as they are usually younger, surgical risks may be lower. However, spontaneous evolution of cognition in MCI is unpredictable and benefit from DBS at this stage may be questionable.

Acknowledgments

This study was supported by a grant from the French national Programme Hospitalier de Recherche Clinique (French Plan National Alzheimer) and sponsored by the Centre Hospitalier Universitaire de Nice. Stimulators and electrodes were provided free by Medtronic, who had no role in the study design and analysis.

Authors' disclosures available online (<http://www.j-alz.com/disclosures/view.php?id=1534>).

REFERENCES

- [1] Plan Alzheimer 2008-2012, <http://www.plan-alzheimer.gouv.fr/>
- [2] Blennow K, de Leon M, Zetterberg H (2006) Alzheimer's disease. *Lancet* **368**, 387-403.
- [3] Querfurth H, LaFerla F (2010) Alzheimer's disease. *N Engl J Med* **362**, 329-344.
- [4] Ihl R, Frölich L, Winblad B, Schneider L, Burns A, Möller H-J (2011) World Federation of Societies of Biological Psychiatry (WFSBP) guidelines for the biological treatment of Alzheimer's disease and other dementias. *World J Biol Psychiatry* **12**, 2-32.
- [5] Dubois B, Feldman H, Jacova C, Dekosky S, Barber-Gateau P, Cummings J, Delacourte A, Galasko D, Gauthier S, Maguro G, O'Brien J, Pasquier F, Robert P, Rossor M, Salloway S, Stern Y, Visser P, Scheltens P (2007) Research criteria for the diagnosis of Alzheimer's disease: Revising the NINCDS-ADRDA criteria. *Lancet Neurol* **6**, 734-746.
- [6] Dubois B, Feldman H, Jacova C, Cummings J, Dekosky S, Barberger-Gateau P, Delacourte A, Frisoni G, Fox N, Galasko D, Gauthier S, Hampel H, Jicha G, Meguro K, O'Brien J, Pasquier F, Robert P, Rossor M, Salloway S, Sarazin M, de Souza L, Stern Y, Visser P, Scheltens P (2010) Revising the definition of Alzheimer's disease: A new lexicon. *Lancet Neurol* **9**, 1118-1127.
- [7] Albert M, DeKosky S, Dickson D, Dubois B, Feldman H, Fox N, Gamst A, Holtzman D, Jagust W, Petersen R, Snyder P, Carrillo M, Thies B, Phelps C (2011) The diagnosis of mild cognitive impairment due to Alzheimer's disease: Recommendations from the National Institute on Aging-Alzheimer's Association workgroups on diagnostic guidelines for Alzheimer's disease. *Alzheimers Dement* **7**, 270-279.
- [8] McKhann G, Knopman D, Chertkow H, Hyman B, Jack C, Kawas C, Klunk W, Koroshetz W, Manly J, Mayeux R, Mohs R, Rossor M, Scheltens P, Carrillo M, Thies B, Weintraub S, Phelps C (2011) The diagnosis of dementia due to Alzheimer's disease: Recommendations from the National Institute on Aging-Alzheimer's Association workgroups on diagnostic guidelines for Alzheimer's disease. *Alzheimers Dement* **7**, 263-269.
- [9] Sperling R, Aisen P, Beckett L, Bennett D, Craft S, Fagan A, Iwatsubo T, Jack C, Kaye J, Montline T, Park D, Reiman E, Rowe C, Siemers E, Stern Y, Yaffe K, Carrillo M, Thies B, Morrison-Bogorad M, Wagster M, Phelps C (2011) Toward defining the preclinical stages of Alzheimer's disease: Recommendations from the National Institute on Aging-Alzheimer's Association workgroups on diagnostic guidelines for Alzheimer's disease. *Alzheimers Dement* **7**, 280-292.
- [10] Petersen R, Smith G, Waring S, Ivnik R, Tangalos E, Kokmen E (1999) Mild cognitive impairment: Clinical characterization and outcome. *Arch Neurol* **56**, 303-308.
- [11] Hamani C, McAndrews M, Cohn M, Oh M, Zumsteg M, Colin M, et al. (2008) Memory enhancement induced by hypothalamic/fornix deep brain stimulation. *Ann Neurol* **63**, 119-123.
- [12] Suthana N, Haneef Z, Stern J, Mukamel R, Behnke E, Knowlton B, Fried I (2012) Memory enhancement and deep-brain stimulation of the entorhinal area. *N Engl J Med* **366**, 502-510.
- [13] Bliss T, Lomo T (1973) Long-lasting potentiation of synaptic transmission in the dentate area of the anesthetized rabbit following stimulation of the perforant path. *J Physiol* **232**, 331-356.
- [14] Ehret A, Haaf A, Jeltsch H, Heimrich B, Feuerstein T, Jackisch R (2001) Modulation of electrically evoked acetylcholine release in cultured rat septal neurons. *J Neurochem* **76**, 555-564.
- [15] Encinas J, Hamani C, Lozano A, Enikolopov G (2011) Neurogenic hippocampal targets of deep brain stimulation. *J Comp Neurol* **519**, 6-20.
- [16] Laxton A, Tang-Wai D, McAndrews M, Zumsteg D, Wennberg R, Keren R, Wherrett J, Naglie G, Hamani C, Smith G, Lozano A (2010) A phase I trial of deep brain stimulation of memory circuits in Alzheimer's disease. *Ann Neurol* **68**, 521-534.
- [17] Stone S, Teixeira C, DeVito L, Zaslavsky K, Josselyn S, Lozano A, Frankland P (2011) Stimulation of entorhinal cortex promotes adult neurogenesis and facilitates spatial memory. *J Neurosci* **31**, 13469-13484.
- [18] Toda M, Hamani C, Fawcett AP, Hutchison W, Lozano A (2008) The regulation of adult rodent hippocampal neurogenesis by deep brain stimulation. *J Neurosurg* **108**, 132-138.
- [19] Vertes R (2005) Hippocampal theta rhythm: A tag for short-term memory. *Hippocampus* **15**, 923-935.
- [20] Williams J, Givens B (2003) Stimulation induced reset of hippocampal theta in the freely performing rat. *Hippocampus* **13**, 109-116.
- [21] American Psychiatric Association. (1994) *Diagnostic and Statistical Manual of Mental Disorders, Fourth Edition (DSM-IV)*, American Psychiatric Press, Washington, DC.
- [22] Van der Linden M, Coyette F, Poitrenaud J, Kalafat M, Calicis F, Wyns C, Adam S (2004) L'épreuve de rappel libre/rappel indicé à 16 items (RL/Rl-16) In *L'évaluation des troubles de la mémoire : Présentation de quatre tests de mémoire épisodique avec leur étalonnage*, Van der Linden et les membres du GREMEM, ed. Solal, Marseille, pp. 25-47.
- [23] Folstein M, Folstein S, McHugh P (1975) "Mini-Mental State": A practical method for grading the cognitive state of patients for the clinician. *J Psychiatr Res* **12**, 189-198.
- [24] Rosen W, Mohs R, Davis K (1984) A new rating scale for Alzheimer's disease. *Am J Psychiatry* **41**, 1356-1364.

- [25] Wechsler D (1999) *Manual for the Wechsler Abbreviated Scale of Intelligence*. The Psychological Corporation, San Antonio, TX.
- [26] Tombaugh T (2004) Trail making test A and B: Normative data stratified by age and education. *Arch Clin Neuropsychol* **19**, 203-214.
- [27] Rey A, Vaivre-Douret L (1960) *Manuel CPA*, ECPA, Paris.
- [28] Schneider L, Olin J, Doody R, Clark C, Morris J, Reisberg B, Schmitt F, Grundman M, Thomas R, Ferris S (1997) Validity and reliability of the Alzheimer's disease cooperative study-clinical global impression of change. The Alzheimer's Disease Cooperative Study. *Alzheimer Dis Assoc Disord* **11**, 22-32.
- [29] Bruss G, Gruenberg A, Goldstein R, Barber J (1994) Hamilton anxiety rating scale interview guide: Joint interview and test-retest methods for interrater reliability. *Psychiatry Res* **53**, 191-202.
- [30] Montgomery S, Asberg M (1979) A new depression scale designed to be sensitive to change. *Brit J Psychiatr* **134**, 382-389.
- [31] Fontaine D, Lanteri-Minet M, Ouchchane L, Lazorthes Y, Mertens P, Blond S, Geraud G, Fabre N, Navez M, Lucas C, Dubois F, Sol J, Paquis P, Lemaire J (2010) Anatomical location of effective deep brain stimulation electrodes in chronic cluster headache. *Brain* **133**, 1214-1223.
- [32] Fontaine D, Lazorthes Y, Mertens P, Blond S, Géraud G, Fabre N, Navez M, Lucas C, Dubois F, Gonfrier S, Paquis P, Lantéri-Minet M (2010) Safety and efficacy of deep brain stimulation in refractory cluster headache: A randomized placebo-controlled double-blind trial followed by a one-year open extension. *J Headache Pain* **11**, 23-31.
- [33] Wilent W, Oh M, Buetefisch C, Bailes J, Cantella D, Angle C, Whiting D (2011) Mapping of microstimulation evoked responses and unit activity patterns in the lateral hypothalamic area recorded in awake humans. Technical note. *J Neurosurg* **115**, 295-300.
- [34] Leone M, Proietti Cecchini A, Franzini A, Broggi G, Cortelli P, Montagna P, May A, Juergens T, Cordella R, Carella F, Bussone G (2008) Lessons from 8 years' experience of hypothalamic stimulation in cluster headache. *Cephalalgia* **28**, 789-797.
- [35] Wilent W, Oh M, Buetefisch C, Bailes J, Cantella D, Angle C, Whiting D (2010) Induction of panic attack by stimulation of the ventromedial hypothalamus. *J Neurosurg* **112**, 1295-1298.
- [36] Sano K, Mayanagi Y, Sekino H, Ogashiwa M, Ishijima B (1970) Results of stimulation and destruction of the posterior hypothalamus in man. *J Neurosurg* **33**, 689-707.
- [37] Maniyar F, Starr P, Goadsby P (2012) Paroxysmal sneezing after hypothalamic deep brain stimulation for cluster headache. *Cephalalgia* **32**, 641-644.
- [38] Barnikol T, Pawelczyk N, Barnikol U, Kuhn J, Lenartz D, Sturm V, Tass P, Freund H (2010) Changes in apraxia after deep brain stimulation of the nucleus basalis Meynert in a patient with Parkinson dementia syndrome. *Mov Disord* **25**, 1505-1526.
- [39] Freund H, Kuhn J, Lenartz D, Mai J, Schnell T, Klosterkoetter J, Sturm V (2009) Cognitive functions in a patient with Parkinson-dementia syndrome undergoing deep brain stimulation. *Arch Neurol* **66**, 781-785.
- [40] Hamani C, Stone S, Garten A, Lozano A, Winocur G (2011) Memory rescue and enhanced neurogenesis following electrical stimulation of the anterior thalamus in rats treated with corticosterone. *Exp Neurol* **232**, 100-104.
- [41] Lemaire J, Frew A, McArthur D, Gorgulho A, Alger J, Salomon N, Chen C, Behnke E, De Salles A (2011) White matter connectivity of the human hypothalamus. *Brain Res* **137**, 143-164.